

Updated International Clinical Recommendations on Scar Management: Part 2—Algorithms for Scar Prevention and Treatment

MICHAEL H. GOLD, MD,* MICHAEL MCGUIRE, MD,^{††} THOMAS A. MUSTOE, MD,[§]
ANDREA PUSIC, MD,^{||} MUKTA SACHDEV, MD,[¶] JILL WAIBEL, MD,[#]
AND CRYSTAL MURCIA, PHD^{**}

BACKGROUND In 2002, an international advisory panel was convened to assess the scientific literature and develop evidence-based guidance for the prevention and treatment of pathologic scarring. Emerging clinical data, new treatment options, and technical advances warranted a renewed literature search and review of the initial advisory panel recommendations.

OBJECTIVE To update the management algorithm for pathologic scarring to reflect best practice standards at present.

MATERIALS AND METHODS Management recommendations were derived from clinical evidence amassed during a comprehensive literature search and from the clinical experience and consensus opinion of advisory panel members.

RESULTS A combination approach using multiple modalities provides the maximum potential for successful treatment of hypertrophic scars and keloids. The advisory panel advocates a move toward more aggressive initial management of keloids, including earlier application of 5-fluorouracil. A growing body of clinical research supports a place in therapy for newer agents (e.g., bleomycin, onion extract, imiquimod, mitomycin C) and laser therapy (pulsed-dye, fractional) for scar management.

CONCLUSION Prevention and treatment of pathologic scarring requires individualized care built upon the principles of evidence-based medicine and continues to evolve in step with technological and scientific advances.

The authors received honoraria from Enaltus, Lumenis, and Merz for their work on this panel.

Despite the efforts of clinicians and researchers to identify highly successful therapies for the management of excessive scarring, meeting the burden of proof to establish effective strategies has remained elusive. Indeed, as yet, no methodology has emerged as the “gold standard” of clinical care. The challenges of cutaneous scar management are the natural consequence of a complex

pathophysiologic mechanism, lack of suitable model systems to evaluate therapeutic efficacy, difficulties in quantifying changes in scar appearance, and the limited amount of data derived from well-designed, prospective, randomized controlled clinical trials. As a result, patient management has historically been driven by clinician experience rather than adherence to

**Gold Skin Care Center and Tennessee Clinical Research Center, Nashville, Tennessee; †University of California, Los Angeles, Los Angeles, California; ††The University of Southern California, Los Angeles, CA; §Division of Plastic and Reconstructive Surgery, Northwestern University, Chicago, Illinois; ||Memorial Sloan-Kettering Cancer Center, New York, New York; ¶Department of Dermatology, Manipal Hospital, Bangalore, India; #Miami Dermatology and Laser Institute, Miami, Florida; **Inkwell Medical Communications, Novelty, Ohio*

For a complete list of the International Advisory Panel Members, see Appendix 1.

© 2014 by the American Society for Dermatologic Surgery, Inc. • Published by Lippincott Williams & Wilkins •
ISSN: 1076-0512 • Dermatol Surg 2014;40:825–831 • DOI: 10.1111/dsu.0000000000000050

a guideline predicated on the edicts of evidence-based medicine.

In an effort to provide practicing clinicians with a framework for scar management that is rooted in clinical evidence, the International Advisory Panel on Scar Management was convened to review the available data on methods for preventing and treating pathologic scarring. The resulting clinical recommendations were published in 2002.¹ In the interim since the inaugural publication, new data have been published and novel agents explored for the treatment of cutaneous scars, thereby necessitating a revision of the practice recommendations set forth by the original advisory panel. Findings from the renewed assessment are presented in this article, which is intended to provide evidence-based treatment algorithms pertinent to a variety of clinical scenarios.

Development of Clinical Recommendations

Clinical recommendations were developed by an international panel of experts in the field of scar management. After completion of a comprehensive

literature search (see Part 1 of the Updated Clinical Recommendations on Scar Management) and individual assessment of prior recommendations, drafts of the prevention and treatment algorithms and accompanying text were reviewed by the chairman and panel during a series of e-mail communications and teleconferences. Where clinical evidence was lacking, management recommendations were based on panel member consensus.

Cutaneous Scar Classification

The advisory panel members concurred that the scar classification system proposed in the 2002 guidance¹ is still appropriate for contemporary use (Table 1).

Cutaneous Scar Grading Systems

A variety of measurement tools have been applied to grade scars on the basis of parameters such as pigmentation, vascularity, thickness, pliability, height or depression, patient acceptability, and comfort. For the most part, scar grading systems are used to quantify changes in scar appearance during treatment, typically in a clinical research setting. Several recent

TABLE 1. Scar Classification

<i>Scar Type</i>	<i>Description</i>
Mature	<ul style="list-style-type: none"> • Light-colored, flat scar
Immature	<ul style="list-style-type: none"> • Red, sometimes itchy or painful, and slightly elevated scar in the process of remodeling • Many will mature normally over time, become flat, and assume a pigmentation that is similar to the surrounding skin, although they can be paler or slightly darker
Linear hypertrophic (eg, surgical/traumatic)	<ul style="list-style-type: none"> • Red, raised, sometimes itchy scar confined to the border of the original surgical incision. This usually occurs within weeks after surgery • May increase in size rapidly for 3–6 months and then, after a static phase, begin to regress • Generally mature to have an elevated, slightly rope-like appearance with increased width, which is variable. Full maturation process may take up to 2 years
Widespread hypertrophic (eg, burn)	<ul style="list-style-type: none"> • Widespread, red, raised, sometimes itchy scar that remains within the borders of the burn injury
Minor keloid	<ul style="list-style-type: none"> • Focally raised, itchy scar extending over normal tissue • May develop up to 1 year after injury and does not regress on its own • Simple surgical excision is often followed by recurrence • May be a genetic abnormality involved in keloid scarring • Typical sites include earlobes
Major keloid	<ul style="list-style-type: none"> • Large, raised (>0.5 cm) scar, possibly painful or pruritic, and extending over normal tissue • Often results from minor trauma and can continue to spread over the years

Table reproduced from Reference 1 with permission from Williams & Wilkins.

publications have assessed the utility of individual scar rating scales and found that available tools (e.g., Vancouver scar scale [VSS], visual analog scale, patient observer scar assessment scale [POSAS]) have value but are generally lacking in terms of validity, clinical evidence, or fulfillment of clinometric requirements.²⁻⁴ Fearmonti and colleagues² concluded that current scales have acceptable consistency and reliability but have limited sensitivity and are at least partially subjective in nature. One advantage of the POSAS relative to other scales is the inclusion of patient assessment, which is considered as an important aspect of scar evaluation.⁴ Moreover, the POSAS has been found to be more consistent and reliable when compared with the widely used VSS.^{2,3} As no single scale has emerged as the gold standard, ease of use, familiarity, and applicability to the clinical scenario may dictate scar scale selection. Given the natural course of scar improvement during healing, the use of any scale must include the parameter of time relative to initial scar formation or subsequent treatment intervention. For routine clinical practice, at minimum, evaluation of size, thickness, symptom severity (e.g., pain, itching), and patient concerns are recommended.

Scar Prevention

Several methods are available for preventing excessive scarring in patients who experience trauma or

undergo surgery, starting with careful attention to surgical techniques and best practices for wound care. Individuals who have experienced hypertrophic or keloid scarring or who undergo surgery to at-risk regions (e.g., breast, thorax) should be considered at elevated risk and treated aggressively. On the basis of available evidence and expert experience, an algorithm for hypertrophic and keloid scar prevention has been developed (Figure 1). Specific recommendations are summarized as follows:

- For high-risk wounds, silicone-based products are the preferred preventative measure. Silicone gel or sheeting should be applied after the incision or wound has epithelialized and maintained for at least 1 month. For silicone gel sheeting, a minimum 12-hour daily wear time is suggested and, if possible, continuous 24-hour coverage with washing twice daily is recommended. Use of silicone gel in cream or ointment form may be preferable to silicone gel sheeting for high-mobility or large areas, use on the face, or in hot humid climates. In severe cases, concurrent intralesional corticosteroid injections are warranted.
- Options for patients at lower but still elevated risk include silicone gel or sheeting (preferred), hypoallergenic microporous tape, or onion extract-containing preparations. Although there is some support for the use of onion extract-containing preparations, studies reporting negative results,

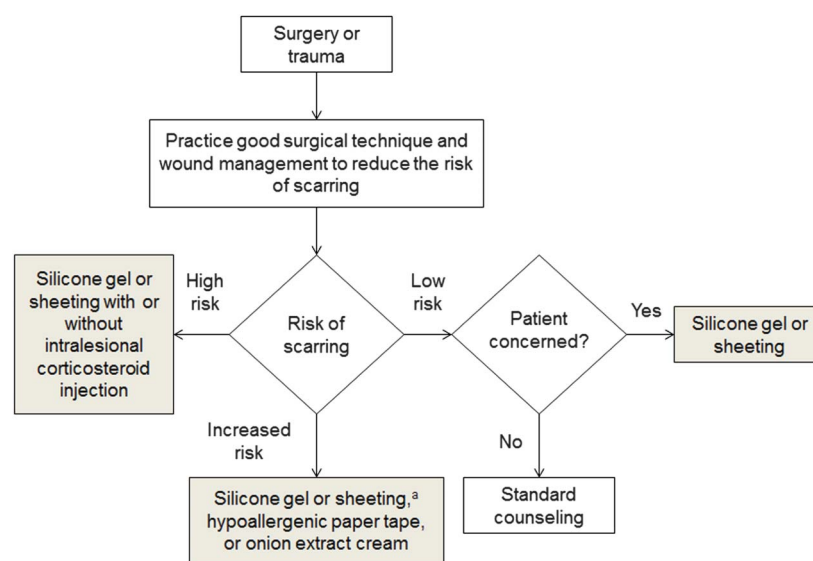


Figure 1. Algorithm for preventing hypertrophic or keloid scars after surgery or trauma. ^aPreferred option. Adapted with permission from Mustoe et al.¹

inclusion of multiple active agents per product, limitations of studies with positive results, and the potential for bias are all factors that preclude an unequivocal recommendation regarding the efficacy of onion extract preparations. If onion extract-containing preparations are used, twice-daily application for up to 3 months is recommended.

- Low-risk patients should be advised to follow standard hygiene practices. If the patient expresses concern regarding the potential for scar formation, silicone gel sheeting or silicone gel may be applied.

Additional Considerations for Scar Prevention

The evidence regarding the effect of solar UV irradiation on the cosmetic appearance of scar tissue is sparse; however, 1 study showed that postoperative sun exposure aggravates the clinical appearance of cicatrices.⁵ Thus, sun protection is vital for minimizing and preventing hyperpigmentation, and sunscreen was proposed as primary protection when skin is exposed to direct sunlight in a clinically relevant animal model.⁶ Ideally, scars should not be exposed to sunlight during the healing period.⁵

Scar Management

Strategies for managing pathologic scarring are largely determined by scar classification. Using the guidance

provided in the scar classification table, scars should be categorized before treatment selection. Treatment algorithms based on scar type are presented in Figures 2 and 3. Patient history of scarring, including past treatment failures or successes, as well as the likelihood of compliance with a chosen therapeutic regimen also influence treatment selection. The presence of symptoms, most frequently pain or pruritus, may necessitate a specific treatment course or adjuvant therapy. Moisturizers, silicone gel sheeting, systemic antihistamines, topical corticosteroids, antidepressants, massage, and hydrotherapy are available options for symptom relief.

Immature or Erythematous Hypertrophic Scars

Because these scars may develop into hypertrophic scars, we advise following the recommendations listed in the prevention algorithm, including the use of silicone gel, hypoallergenic paper tape, and onion extract-containing formulations. In the case of persistent erythema for more than a month despite preventative efforts, management should transition to that of a linear hypertrophic scar (see Linear Hypertrophic Scars Arising From Surgery or Trauma for details) or, alternatively, pulsed-dye laser therapy may be applied once monthly for 2 to 3 months. If the scar is unresponsive to the pulsed-dye laser, fractional laser therapy or treatment as a linear hypertrophic scar may be instituted.

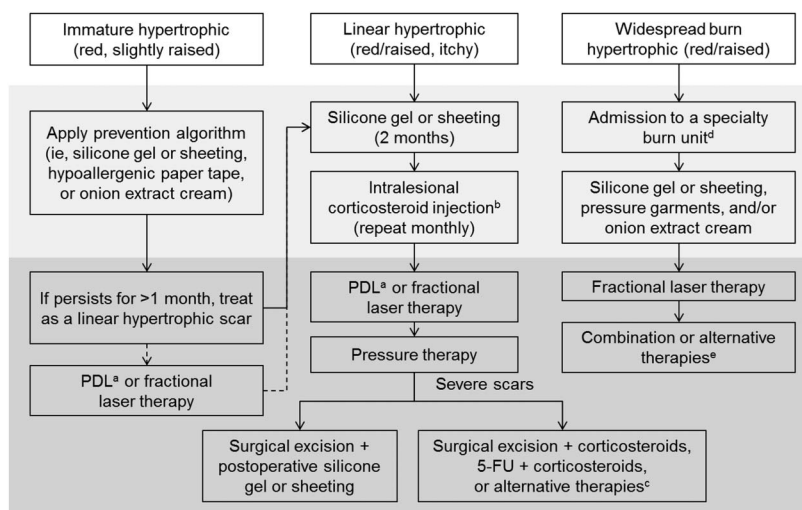


Figure 2. Management algorithm for hypertrophic scars. Light gray indicates initial management strategies; dark gray indicates secondary management options. PDL, pulsed-dye laser. ^aPreferred initial option. ^b2.5 to 20 mg/mL (face); 20 to 40 mg/mL (body). ^cAlternative therapy options for severe lesions include bleomycin, mitomycin C, laser therapy, and cryotherapy. ^dScar prevention and treatment should not begin before epithelium and wound stabilization. ^eCombination and alternative therapies include massage, physical therapy, corticosteroids, tension-relieving surgical intervention, excision, grafting or flap coverage, hydrocolloid dressings, antihistamines, and laser therapy.

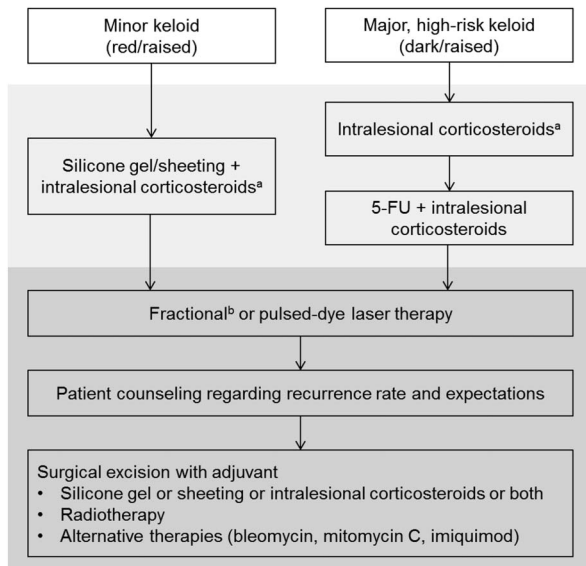


Figure 3. Management algorithm for keloids. Light gray indicates initial management strategies; dark gray indicates secondary management options. ^aCryotherapy may be used in conjunction with intralesional corticosteroids, depending on physician experience and comfort with its application. ^bAblative fractional lasers are the preferred initial laser therapy option for patients with minor keloids.

Linear Hypertrophic Scars Arising From Surgery or Trauma

On the basis of available data from randomized controlled trials, silicone gel or sheeting is the preferred first-line therapy for the treatment of linear hypertrophic scars. In cases where a 2-month course of silicone gel or sheeting does not prove effective or when the scar is severe, pruritic, or both, adjunctive use of intralesional corticosteroid injection or 5-fluorouracil (5-FU) is indicated. Clinicians should be aware of contraindications to the use of 5-FU, including anemia, leukopenia, thrombocytopenia, pregnancy, bone marrow depression, and infection. Side effects of 5-FU are generally localized and include pain at the injection site, hyperpigmentation, skin irritation, and ulceration.

Pulsed-dye or fractional laser therapy are second-line and, often, first-line options for linear hypertrophic scars. Pressure therapy may also be applied in cases that do not resolve with first-line treatment options. Pressure therapy alone is unlikely to be sufficient in most patients. If a 12-month period of conservative therapy is unsuccessful, surgical excision to

relieve tension and postoperative application of silicone gel or sheeting should be considered. Surgical intervention is a clear option for the treatment of excessive scarring that develops as a consequence of delayed wound healing or when scarring creates functional impairment. The presence of tension in scars is a major factor in the development of hypertrophy. Understanding the role of tension in the pathophysiology of an individual scar is important when forming a treatment plan. When contraction is significant and hypertrophy is present, surgical relief of tension is necessary. In the absence of overt tension, it is recommended that hypertrophic scars be allowed the opportunity to regress on their own; a 1-year waiting period has been proposed before proceeding to surgical intervention. This waiting period is also important if the scar is still active with evidence of inflammation; the panel believes that outcomes from surgical excision are less favorable in these cases.

In terms of surgical techniques, Z-plasty or W-plasty is appropriate for reducing scar tension and thereby reducing the risk of recurrence. A small-wave incision method (or S-plasty) has also been used in long, linear hypertrophic scar reconstruction with favorable results.⁷ Skin graft or local flaps may be used in the treatment of larger scars. Suturing techniques that result in prolonged relief of tension are useful. Adjuvant therapy is advised after surgery to prevent scar recurrence, but no single strategy has emerged as the preferred treatment option. Advanced biologic therapies, such as dermal scaffolds, matrices, or epithelial cell suspensions, designed to foster wound healing may prove beneficial for scar management after surgical intervention but have not been well studied for this application.

For severe scars, surgical excision may be accompanied by layering of triamcinolone, long-term placement of intradermal sutures, and subsequent monthly corticosteroid administration. Severe scars may also benefit from concomitant intralesional 5-FU (0.9 mL of a 50 mg/mL solution) and corticosteroid injections (e.g., 0.1 mL of triamcinolone acetonide 40 mg/mL) administered monthly or treatment with newer agents, such as bleomycin or mitomycin C. Bleomycin is administered as multiple intralesional injections

(1.5 IU/mL) or through topical application after multiple surface punctures (a technique known as tattooing). Two or more treatment sessions may be needed to achieve clinical benefit. Hyperpigmentation and skin atrophy have been reported with bleomycin treatment.⁸ Mitomycin C protocols vary; it is the opinion of the advisory panel that application of mitomycin C 0.4 mg/mL for 5 minutes is appropriate, with the overall amount used depending on the size of the scar.

Widespread Burn Hypertrophic Scars

Patients with widespread burns should be admitted to a specialty burn unit for care. Once the epithelium is intact and stable, scar prevention and therapy may be initiated. Clinical evidence supports the use of silicone gel preparations as first-line therapy. Pressure garments and onion extract-containing formulations may also be used, although the body of evidence is not as robust. Positive data for fractional lasers support their use for burn scar treatment. Ablative fractional lasers offer the advantage of fewer treatment sessions compared with nonablative options. The complexity of managing burn scars will often require personalized management consisting of combination or alternative therapies including: silicone gel sheeting; individualized pressure therapy; massage, physical therapy, or both; corticosteroid application; and surgical procedures. Massage, hydrocolloids, and antihistamines may be added to the therapeutic regimen to relieve pruritus.

Minor Keloids

First-line therapy for the treatment of minor keloids involves the combination of silicone gel or sheeting with monthly intralesional corticosteroid injections. Contact or intralesional cryotherapy is a potentially useful adjunct for these lesions, but it has yet to reach widespread use for keloid management in clinical practice. Administration of an oral analgesic and translesional local anesthesia can be used to reduce pain experienced during cryotherapy.⁹

If improvement with conservative therapy is not observed within 8 to 12 weeks, 5-FU in combination with intralesional corticosteroids and, ultimately, laser therapy or surgical excision may be considered. Although data from published clinical trials are lacking,

some advisory panel members suggest the use of ablative fractional lasers over other types of laser therapy for the treatment of refractory keloids. Given the significant potential for recurrence after surgical removal, patients should be counseled beforehand regarding their expectations and possible outcomes. Partial excision of the keloid is preferred if full excision poses a risk of structural damage or deformity. Surgical solutions with regional or distal flaps are appropriate for some keloids.

To prevent keloid recurrence after surgery, adjunctive therapies should be applied. Silicone gel or sheeting and intralesional corticosteroids are among the more conservative approaches to postoperative keloid prophylaxis. In carefully selected patients, radiotherapy after surgical excision is a viable treatment option. Intralesional 5-FU is the most recent therapy for which the evidence of success is the best. When added to surgical excision, chemotherapeutic agents that interfere with cell growth, such as bleomycin and mitomycin C, as well as 5% imiquimod cream merit consideration in the treatment of refractory keloids. Although not an approved indication for the use of imiquimod 5% cream, there is some support for nightly application to the surgical incision site starting 2 to 3 weeks after excision of keloids and persisting for 2 months, as tolerated. Mild irritation or skin abrasions and hyperpigmentation have been reported with imiquimod use.¹⁰ Temporary cessation of therapy may be necessary for resolution of local side effects.

Major Keloids

Major keloids present a considerable challenge to clinical management. Major keloids are often refractory to treatment and have a high probability of recurrence after excision. On the basis of clinical evidence and experience, the advisory panel advocates monthly intralesional corticosteroid administration with or without adjuvant cryotherapy as a first-line option for treating major keloids. If this strategy is not effective within 3 to 4 months, transition to therapy with monthly intralesional 5-FU and triamcinolone is recommended. Secondary management options for refractory keloids include laser treatment and surgical excision with appropriate prophylactic therapy. Referral to a clinician experienced in keloid

management is suggested for patients with difficult, recurrent, or refractory lesions.

Conclusion

The prevention and management of pathologic scarring continues to evolve as new treatment modalities are introduced, clinical evidence better quantifies therapeutic efficacy, and experience refines best practice guidance. It is the hope of this advisory panel that critical assessment and consensus, such as those provided in this guidance, will allow clinicians to select treatment options that have the best chance of successful outcomes for their patients. In the current era, this will often mean a combination approach to management that is individualized to scar-specific and patient-specific parameters.

Acknowledgments We thank Brian Berman, MD, PhD, Matteo Tretti Clementoni, MD, Gerd G. Gauglitz, MD, and Foad Nahai, MD, for their input and review of the manuscript; and Jennifer Rossi, MedThink SciCom, for providing editorial support.

References

1. Mustoe TA, Cooter RD, Gold MH, Hobbs FD, et al. International clinical recommendations on scar management. *Plast Reconstr Surg* 2002;110:560–71.
2. Fearmonti R, Bond J, Erdmann D, Levinson H. A review of scar scales and scar measuring devices. *Eplasty* 2010;10:e43.
3. Tyack Z, Simons M, Spinks A, Wasiak J. A systematic review of the quality of burn scar rating scales for clinical and research use. *Burns* 2012;38:6–18.
4. van der Wal MBA, Verhaegen PDHM, Middelkoop E, van Zuijlen PPM. A clinimetric overview of scar assessment scales. *J Burn Care Res* 2012;33:e79–87.
5. Due E, Rossen K, Sorensen LT, Kliem A, et al. Effect of UV irradiation on cutaneous cicatrices: a randomized, controlled trial with clinical, skin reflectance, histological, immunohistochemical and biochemical evaluations. *Acta Derm Venereol* 2007;87:27–32.
6. Brown RJ, Lee MJ, Sisco M, Kim JY, et al. High-dose ultraviolet light exposure reduces scar hypertrophy in a rabbit ear model. *Plast Reconstr Surg* 2008;121:1165–72.
7. Huang C, Ono S, Hyakusoku H, Ogawa R. Small-wave incision method for linear hypertrophic scar reconstruction: a parallel-group randomized controlled study. *Aesthetic Plast Surg* 2012;36:387–95.
8. Saray Y, Güleç AT. Treatment of keloids and hypertrophic scars with dermojet injections of bleomycin: a preliminary study. *Int J Dermatol* 2005;44:777–84.
9. Mirmovich O, Gil T, Goldin I, Lavi I, et al. Pain evaluation and control during and following the treatment of hypertrophic scars and keloids by contact and intralesional cryosurgery—a preliminary study. *J Eur Acad Dermatol Venereol* 2012;26:440–7.
10. Berman B, Viera MH, Amini S. Keloid and hypertrophic scar treatment & management. In: Elston DM, editor. *Medscape reference: drugs, diseases and procedures*; 2012. Available at: <http://emedicine.medscape.com/article/1057599-treatment>.

Address correspondence and reprint requests to: Michael H. Gold, MD, Gold Skin Care Center and Tennessee Clinical Research Center, 2000 Richard Jones Road, Suite 220, Nashville, TN 37215, or e-mail: goldskin@goldskincare.com