

# Injectable Non-Animal Stabilized Hyaluronic Acid as a Skin Quality Booster: An Expert Panel Consensus

Magda Belmontesi MD,<sup>a</sup> Francesca De Angelis MD PhD,<sup>b</sup> Carlo Di Gregorio MD PhD,<sup>c</sup> Ivano Iozzo MD,<sup>d</sup>  
Marina Romagnoli MD,<sup>e</sup> Giovanni Salti MD,<sup>f</sup> and Matteo Tretti Clementoni MD<sup>g</sup>

<sup>a</sup>Studio Medico Belmontesi, Vigevano, Italy

<sup>b</sup>De. A. Center Laser & Plastic Surgery Clinic, Naples, Italy

<sup>c</sup>Plastic Surgeon, Palermo, Italy

<sup>d</sup>CMIA Medical Center, Bologna, Italy

<sup>e</sup>Studio Dermatologico Ligure, Genoa, Italy

<sup>f</sup>Aesthetic Plastic Surgery, Istituto Medlight, Florence, Italy

<sup>g</sup>Laserplast, Milan, Italy

## ABSTRACT

Hyaluronic acid (HA) is used extensively in aesthetic medicine thanks to its documented role in skin rejuvenation. The specific applications of HA-based products are not always fully acknowledged due to a lack of consistent recommendations. In this paper, the authors have summarized available published data on the range of applications of non-animal stabilized hyaluronic acid (NASHA<sup>®</sup>) gel skin boosters (NSBs) in several anatomical areas and types of patient, as well as their own recommendations.

Overall, the panel agreed that a standard initial protocol treatment of up to 3 sessions, followed by a maintenance schedule, would allow patients to improve and then preserve skin quality over time. Indeed, distinct effects are evident after the first session, but a progressive enhancement of skin texture is detectable for up to 12 months after repeat treatment at 4 to 6 month intervals. Moreover, the authors agreed that the NASHA gel, reaching the dermis, is able to reestablish a greater degree of hydration and stimulate collagen that, in turn, restores the volume and density of the skin. Thus, a strong consensus was reached that NSB procedures are minimally invasive, safe, and effective, and designed to improve skin texture and maintain skin quality.

*J Drugs Dermatol.* 2018;17(1):83-88.

## INTRODUCTION

The increasing psychosocial importance of skin health is driving the development of new cosmetic treatments and approaches;<sup>1</sup> and hyaluronic acid (HA) has a documented role in skin rejuvenation because, due to its viscoelastic properties, it develops a condensed network within the connective tissue to attract water into its own matrix and improve skin turgor.<sup>2-4</sup> Recent data indicate also that HA promotes the release of cell growth factors, as well as increasing the production of collagen fibres and modulating their elongation.<sup>5-8</sup> Mesotherapy injection procedures are based on native HA-based substances, with some formulations including collagen or a mixture of additional substances (vitamins, amino acids, and coenzymes) supposed to promote fibroblast stimulation.<sup>9</sup> However, there is an ongoing debate about the factual efficacy of mesotherapy in inducing skin rejuvenation due to the controversial data on its in vivo efficacy and long-term change of collagen fibres.<sup>10-12</sup>

Since the 1990s, different manufacturing processes have been used to prolong the persistence of HA into the tissue by creating

a molecule resistant to degradation while preserving its natural entanglements.<sup>13-16</sup>

Non-animal stabilized hyaluronic acid (NASHA<sup>®</sup>) gels are based on a patented technology that uses a low degree of chemical cross-linking and preserves natural HA entanglements, and they have been among the most extensively documented and commonly used gels for soft tissue augmentation over the last 20 years.<sup>16-18</sup> Restylane Skinboosters<sup>®</sup> Vital and Restylane Skinboosters<sup>®</sup> Vital Light (Q-Med AB / Galderma, Uppsala, Sweden) are NASHA gels specifically designed to progressively improve skin quality through intradermal or subdermal injection in very small aliquots. They have been used in Europe for more than 12 years and shown to be effective in the face, hands, neck, and décolletage.<sup>5, 19-22</sup>

Due to a lack of consistent recommendations on the approach to consultation, assessment, injection technique, and ways to optimize the treatment effect, there is misunderstanding regarding the use of such products. The authors here provide

© 2018-Journal of Drugs in Dermatology. All Rights Reserved.

This document contains proprietary information, images and marks of Journal of Drugs in Dermatology (JDD).

No reproduction or use of any portion of the contents of these materials may be made without the express written consent of JDD.

If you feel you have obtained this copy illegally, please contact JDD immediately at support@jddonline.com

consensus recommendations on the clinical use of NASHA gel skin boosters (NSBs) that reflect the published data and their own experience of more than 10 years.

## METHODS

In 2015, 7 experts in dermatology, plastic surgery, and aesthetic surgery convened to discuss the available literature and share their experiences with the aim of developing consensus recommendations on the appropriate use of NSBs, specifically in regards to patient selection; indications and skin effects in different anatomical areas; injection techniques; treatment protocol; and duration of clinical effects. Consensus was defined as approval of more than 57% of all participants, whereas agreement of more than 85% denoted a strong consensus. The board met again in December 2016 to finalize their recommendations. This document should be considered as expert opinion and is not intended to be a standard-of-care guideline.

## RESULTS

### Patient Selection: Whom to Treat?

NSBs have been used in individuals with different skin types and ethnic origins and aged between 20 and 65 years.<sup>19-24</sup> The authors support the use of NSBs in a wider age range, between 18 and 70+ years, specifying that the skin baseline status, rather than the patient's age, should determine suitability for treatment. Regardless of age, the NSB treatment should be matched with an appropriate protocol and NSB formulation. According to the authors, 20 mg/mL NSB gel is particularly suitable for counteracting signs of aging such as skin roughness, fine lines, and sagging skin, while the 12 mg/mL NSB is suitable for preventing skin aging in younger patients and, for all ages, in treatment areas with delicate and/or thin skin.

### Which Indications?

The authors achieved optimal clinical results and consensus in the following areas (Table 1):

#### Face/Cheeks

The use of NSBs in the face and cheeks is strongly supported by the board. Two studies have highlighted the role of NSB 20 mg/mL gel in these areas. In both studies, a series of 3 sessions (1 mL/session), 4 weeks apart, were carried out, with results showing a significant improvement in extensibility, elasticity, and fatigability ( $P < 0.005$ ) and a significant decrease in skin roughness.<sup>19,21</sup> Eighty-five percent of subjects rated the outcome as "very good" or "good". A recent study has shown a significant improvement in skin elasticity and hydration on the cheeks at 4 weeks and up to 12 weeks after only 1 session.<sup>25</sup> Regarding the forehead area, the authors recommend injecting the softer and more malleable NSB 12 mg/mL gel by using a blunt cannula. More robust gels in this area, or injection by a sharp needle, could cause pain, risk of vascular injury, and palpable lumps.

**TABLE 1.**

Areas Indicated for Treatment With NSBs		
Area	Consensus	References
Face and cheeks	Yes*	5, 19, 21, 25, 27
Forehead lines	Yes	-
Hands	Yes*	5, 20, 22, 27
Upper arms	Yes*	24
Neck and décolleté	Yes*	5, 22, 27
Perioral lines	Yes*	22
Periorbital lines	Yes*	22
Skin signs of solar elastosis	Yes*	21
Lips	Yes*	2, 26
Other: knees, elbows, back of foot	No	27

\*Indicates strong consensus with agreement of >85%.

#### Periorbital, Perioral Area, and Lips

Significant overall improvements in skin elasticity and hydration with a 3-session regimen NSB 12 mg/mL gel, 21 days apart, have been documented in the periorbital and perioral lines.<sup>23</sup> The authors agree on the preferential use of the softer, more malleable 12 mg/mL NSB in these areas with thinner dermis and more mobility. The authors underline the good aesthetic results of injecting NSB 20 mg/mL gel into the lips to improve plumpness and the appearance of superficial wrinkling.<sup>2,26</sup>

#### Neck and Décolleté

The authors agreed on the efficacy and safety of the injection of NSB 12 mg/mL gel to improve overall skin quality and elasticity in the neck and décolleté area, in line with current clinical data.<sup>22,23</sup>

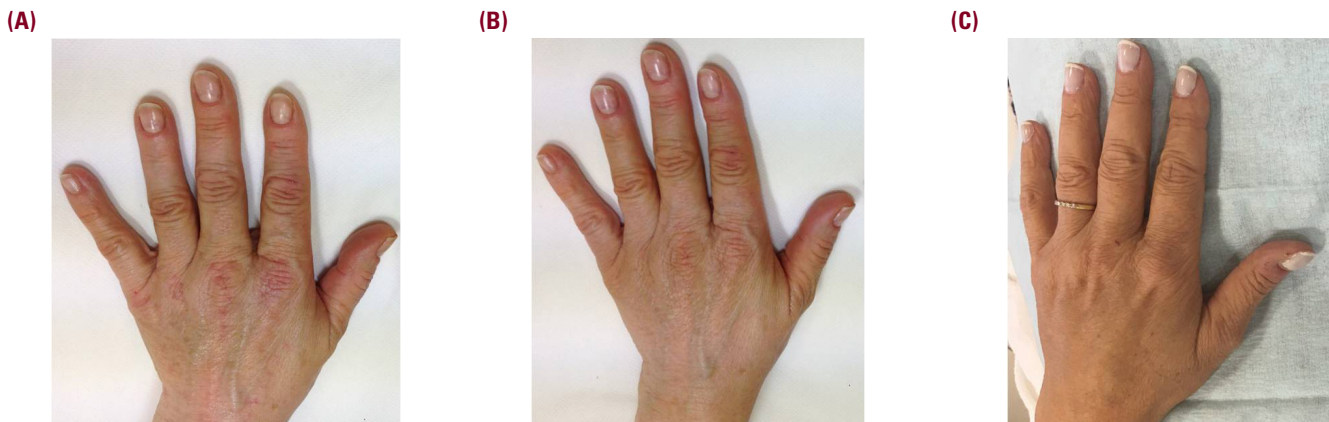#### Hands and Arms

The authors recommend the use of NSBs to improve the skin quality of the dorsal hands, as significant effects have been obtained in clinical practice and in different studies.<sup>20,22,27</sup> In a 3-month treatment study with NSB 20 mg/mL gel (1 mL/session), patients experienced a significant increase of stratum corneum hydration and skin elasticity, while surface roughness decreased. Importantly, results were maintained up to 12 months.<sup>22</sup>

Results from another study using NSB 20 mg/mL gel in women with loose inner upper arm skin (1 mL/arm for 3 sessions) demonstrated increased hydration of the stratum corneum and dermal thickness, and an enhancement of gross elasticity and cutaneous firmness.<sup>24</sup>

#### Other Body Areas

Most of the authors have little or no experience of injecting NSBs into the elbows, knees, or back of foot. A recent study

**FIGURE 1.** Dry atopic skin. (A) Before treatment with NSBs. (B) 3 months after 2 sessions. (C) 8 months after 4 sessions.

in 150 women after injection of NSB 20 mg/mL gel with a mesogun for dry skin treatment of the face, hands, elbows, legs, and hips showed a significant improvement in skin roughness, morphology, thickness, and hydration.<sup>25,27</sup>

### Emerging Indications

#### *Can be Used With Other Procedures in Combined Protocols*

Most experts report successful results using NSBs in combination with other skin rejuvenation procedures, such as peelings, lasers, or other physical technology. In a small pilot study, NSB 12 mg/mL gel was injected into the neck, followed immediately by fractional non-ablative micro thermal laser treatment (4 sessions, one every 2 to 4 weeks).<sup>28</sup> Histological examination from skin biopsies revealed an increase in dermal collagen and elastic fibers, as well as clinical improvements of fine wrinkles, laxity, and skin texture.<sup>28</sup>

All the authors strongly disagree with the use of both procedures in the same session, and recommend administering them in separate sessions, scheduling NSB before laser treatment in order to improve dermal hydration and optimize laser action. In clinical practice, four authors apply a protocol based on 1 or 2 sessions of NSB before the first laser treatment, followed by alternate sessions of NSB and laser 2 weeks apart.

#### *Improvement of Depressed Acne Scars*

The authors agree, in line with published literature, that NSBs can be used as a therapy to improve the appearance of depressed acne scars, likely due to the HA's ability to stimulate collagen production.<sup>6,29,30</sup> Rolling scars and, to a lesser extent, box scars are the most suitable subtype to treat, while poorer results are seen for ice pick and deep scars. Injection technique may require prior deep fibrous detachment by a needle. A significant improvement in acne scars has been reported with 3-monthly subcutaneous injections of NSB 20 mg/mL with a blunt cannula.<sup>29</sup> The panel agreed on the benefit of combining NSB treatment with ablative or non-ablative fractional laser in

separate sessions. In the literature, patients with moderate/severe facial acne scarring underwent injections of NSB 20 mg/mL after completing fractional laser resurfacing.<sup>30</sup>

### Other Conditions

Based on the experience of treating 10 cases, the authors agreed that NSBs can be potentially used for enhancing the quality of thin and atrophic skin in patients under treatment with tamoxifen or corticosteroids. Promising results have been obtained in improving dry atopic skin (Figure 1). In a recent report, the repeated injection of NSB 12 mg/mL and the larger particle NASHA® gel (Restylane® Perlane, Q-Med AB / Galderma, Uppsala, Sweden) led to the progressive correction of a corticosteroid injection-related tissue atrophy. A complete correction was achieved at 1 month after the last treatment session and lasted for more than 18 months. The result is likely related to the stimulation of collagen production and tissue regeneration induced by the repeated treatments.<sup>31</sup>

### Which Effect?

NSBs have demonstrated high efficacy on overall skin quality (Table 2). The authors agreed on defining NSB as a medical treatment for the skin that has a double effect on texture appearance

**TABLE 2.**

Consensus Recommendations on the Effects of NSB		
	Consensus	Reference
Improves skin elasticity	Yes*	6, 20-24
Reduces texture/surface roughness	Yes*	6, 20-24, 28
Improves skin firmness	Yes*	19, 20, 24
Improves hydration	Yes*	20, 22, 23
Reduces fine wrinkles	Yes*	23, 28, 29
Reduces skin imperfections	Yes*	29-31

\*Indicates strong consensus with agreement of > 85%

and skin structure, with profound differences from both fillers and non cross-linked gels used in mesotherapy.

### Injection Techniques

NSBs should be injected into the reticular dermis or subdermis, where the product is naturally integrated and highly effective. The multiple micro-puncture injections of a dosed amount of gel is the first choice technique; however, factors such as the treatment area, skin thickness, and severity of aging signs must be considered. All the authors strongly agreed that the SmartClick™ system of the NSB syringe ensures high precision during the injection because it allows delivery of a constant depot of gel (~10 µL) for each click. The injections should be carried out by inserting almost the entire length of the needle into the dermis or subdermis at a 25°-30° angle to the skin surface. Typically, 2 to 3 10 µL depots are delivered during the linear extraction of the needle.

When the SmartClick™ system is not activated, the injection is carried out under physician control, releasing the gel in small separate depots or by continuous linear threading (Figure 2). Whatever option is chosen, the authors recommend stopping injection before extracting the last 2 mm to 3 mm of the needle from the skin to avoid injecting superficially and creating visible or palpable product.

The authors agree that a total amount of 1 mL to 2 mL/session is usually required to treat the whole face; 2 mL at the first session is commonly required to treat more photoaged skin, the hands, or the arms. Usually, injections are spaced 1 cm apart, but gel amounts and number of injections may vary or a linear threading technique be preferred in the case of a specific case defect or in severe ageing conditions. The target depth of injection is the dermis or immediate subdermis to avoid visible or palpable product.


NASHA® gel can be delivered subcutaneously with a blunt cannula; however, the authors agreed that the injection into the subcutaneous plane with a cannula could create a filler-like volumizing effect.<sup>5,29</sup> A deeper injection plan could reduce the effect on skin texture compared with intradermal/sub dermis injection.<sup>27</sup> The authors agreed that cannula should be used in the treatment of the dorsum of the hands and feet, in the neck area, and to stimulate the subdermal adipose tissue.<sup>32,33</sup>

### Protocol


The start-up treatment protocol is usually carried out in 2 to 3 sessions, with the second session 4 to 6 weeks later. The authors agreed that younger skin can experience visible benefits after just 1 session. In a cohort of 25 Asian subjects (age 37 + 8 years), efficacy was seen at week 12 after 1 NSB treatment session by mesogun.<sup>25</sup> Depending on the baseline skin quality and condition, and the degree of clinical response elicited, the treatment protocol may vary. Once the desired clinical effect

**FIGURE 2.** Injection technique of NSBs in the deep dermis/subdermis. (A) Separate small depots of gel delivered during the linear extraction of the needle. (B) Continuous linear threading.

(A)



(B)



is reached, maintenance treatment is carried out every 4 to 6 months.

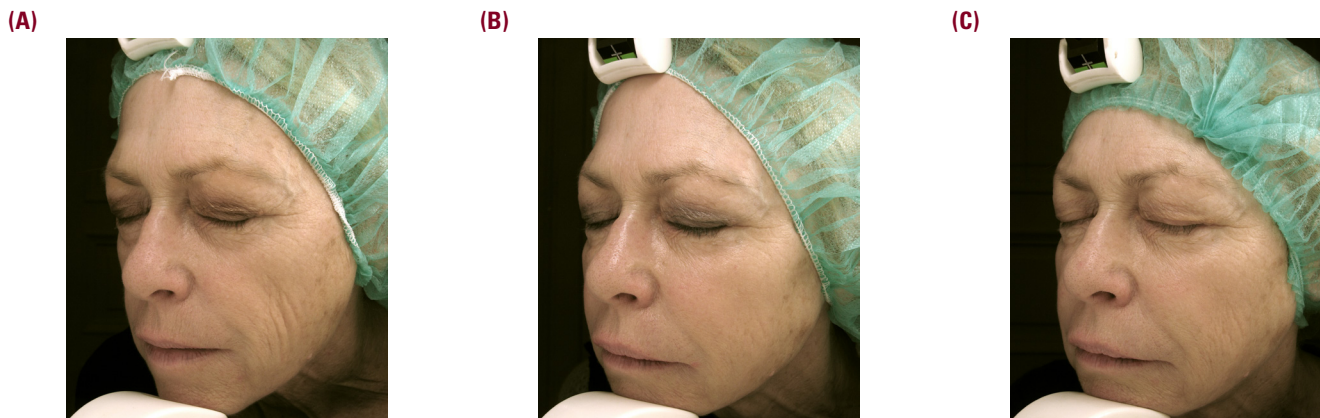
### Progressive and Long-Lasting Effects

The long-term efficacy of NSB has been demonstrated in clinical practice and in published studies documenting skin benefits at 12 or 24 weeks after treatment, whereas non-stabilized HA did not show such duration of effect.<sup>19-24</sup>

Published studies have highlighted how NSBs can stimulate fibroblast activity. Indeed, the results of a histological and immune-histochemical study carried out to analyze the NASHA formulation clearly show its significant capacity to induce synthesis of type I collagen and procollagen in vivo due to stimulation of the fibroblast through mechanical stretching in the reticular dermis.<sup>5</sup> Increased collagen production has been associated with increased levels of signaling molecules and growth factors.<sup>6,34</sup> Moreover, it has been observed that procollagen synthesis remains up-regulated for weeks after the end of the treatment, making NASHA an ongoing trigger factor for collagen production.<sup>6</sup> For these reasons, regular retreatment is critical to maintain the ongoing tissue activation and continued stimulation of the dermal matrix.<sup>8,26,35</sup>

The production of new collagen could be just one of the possible mechanisms for the long-lasting effects of stabilized HA. Recently, adipocytes, present both in dermis and in adipose tissue, have been shown to possess a high plasticity; thus,

**FIGURE 3.** Long-term improvement of skin quality after 3 monthly sessions with NSBs. (A) Baseline. (B) 1 month after 3 sessions. (C) 9 months after 3 sessions.

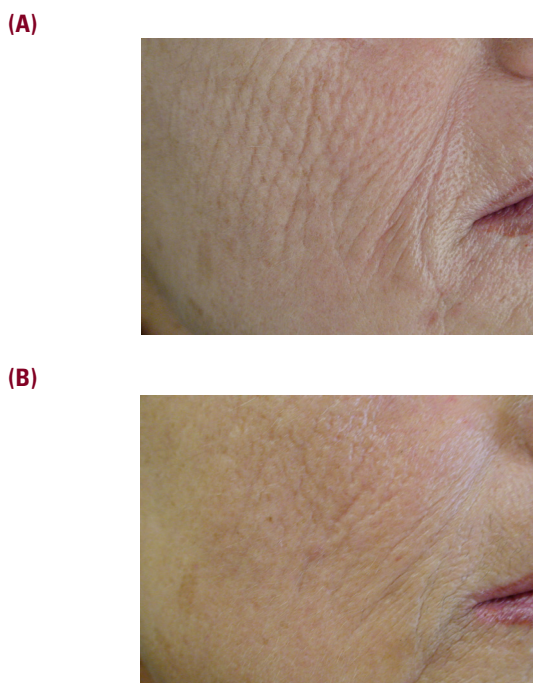


promoting the hypertrophy of these cellular types could lead to a prolonged increase in tissue volume.<sup>36-37</sup>

### DISCUSSION AND CONCLUSIONS

Objective data from 10 years of published studies highlight that NSBs can rejuvenate aged skin. The authors have here achieved strong consensus on the effectiveness and safety of NSB gels in treating signs of photo- and chrono-aging and leading to the enhancement and maintenance of improved skin quality. Following a series of treatments timed to a protocol that reflects the baseline skin quality, treatment objective, and degree of

**FIGURE 4.** Results after 3 monthly sessions with NSBs. (A) Baseline. (B) After 6 months.



clinical response to the initial injection sessions should allow subjects to control and maintain their improved skin quality over time. In fact, though skin benefits are seen within 15 days, the progressive improvement of skin structure over the first 6 months will be maintained for 9 to 12 months after 2 to 3 sessions (Figures 3-4).

Importantly, NSBs hold high satisfaction rates among the patients. The authors strongly agreed that, thanks to the unique stabilization technology, the risk of procedure or gel related adverse events is very low. The most common adverse events are mild and resolve spontaneously in 2 to 7 days, including pain on injection, swelling, and bruising. Delayed swelling, nodule formation, and skin reaction are rare.

In conclusion, the authors recognized NSBs as a first-line treatment among the HA-based injectable procedures for skin care, and described their key features:

- The manufacturing process of these skin boosters enables the production of a smoother small gel particle size, still able to elicit stimulation of the fibroblasts.
- Versatility, since they can be used by a wide spectrum of patients and skin types.
- Scientifically proven efficacy, thanks to the solid scientific literature from the last 10 years proving its efficacy and safety.
- Innovation, since these products are now used with a controlled microinjection delivery system, leading to the ability to standardize the aliquot dose delivered to the tissue.

### DISCLOSURES

Editorial assistance for this manuscript was supported by Galderma. All authors received travel support or honoraria to

attend the meetings associated with the development of the Consensus; and have no other conflicts of interest to declare.

## REFERENCES

- Weeks DM, Thomas JR. Beauty in a multicultural world. *Facial Plast Surg Clin North Am.* 2014;22:337-341.
- Bertucci V, Lynde CB. Current concepts in the use of small-particle hyaluronic acid. *Plast Reconstr Surg.* 2015;136:132s.
- Rohrich RJ, Ghavami A, Crosby MA. The role of hyaluronic acid fillers (Restylane) in facial cosmetic surgery: review and technical considerations. *Plast Reconstr Surg.* 2007;120:41s-54s.
- Salwowska NM, Bebenek KA, Żądło DA, Wcisło-Dziadecka DL. Physicochemical properties and application of hyaluronic acid: a systematic review. *J Cosmet Dermatol.* 2016;15:520-526.
- Streker M, Reuther T, Krueger N, Kerscher M. Stabilized hyaluronic acid-based gel of non-animal origin for skin rejuvenation: face, hand, and décolletage. *J Drugs Dermatol.* 2013;12:990-994.
- Wang F, Garza LA, Kang S, et al. *In vivo* stimulation of de novo collagen production caused by cross-linked hyaluronic acid dermal filler injections in photodamaged human skin. *Arch Dermatol.* 2007;143:155-163.
- Landau M, Fagien S. Science of hyaluronic acid beyond filling: fibroblasts and their response to the extracellular matrix. *Plast Reconstr Surg.* 2015;136:188s-195s.
- Quan T, Wang F, Shao Y, et al. Enhancing structural support of the dermal microenvironment activates fibroblasts, endothelial cells, and keratinocytes in aged human skin *in vivo.* *J Invest Dermatol.* 2013;133:658-667.
- Prikhnenko S. Polycarbonate mesotherapy formulations for the treatment of skin aging and improvement of skin quality. *Clin Cosmet Investig Dermatol.* 2015;8:151-157.
- Lacarrubba F, Tedeschi A, Nardone B, Micali G. Mesotherapy for skin rejuvenation: assessment of the subepidermal low-echogenic band by ultrasound evaluation with cross-sectional B-mode scanning. *Dermatol Ther.* 2008;21:s1-s5.
- Amin SP, Phelps RG, Goldberg DJ. Mesotherapy for facial skin rejuvenation: a clinical, histological, and electron microscopic evaluation. *Dermatol Surg.* 2006;32:1467-1472.
- El-Domyati M, El-Ammawi TS, Moawad O, et al. Efficacy of mesotherapy in facial rejuvenation: a histological and immunohistochemical evaluation. *Int J Dermatol.* 2012;51:913-919.
- Sundaram H, Cassuto D. Biophysical characteristics of hyaluronic acid soft-tissue fillers and their relevance to aesthetic applications. *Plast Reconstr Surg.* 2013;132:5s-21s.
- Kablik J, Monheit GD, Yu L, et al. Comparative physical properties of hyaluronic acid dermal fillers. *Dermatol Surg.* 2009;35:302-312.
- Tezel A, Fredrickson GH. The science of hyaluronic acid dermal fillers. *J Cosmet Laser Ther.* 2008;10:35-42.
- Edsman K, Nord LI, Ohrlund A, et al. Gel properties of hyaluronic acid dermal fillers. *Dermatol Surg.* 2012;38:1170-1179.
- Glogau RG, Bank D, Brandt F, et al. A randomized, evaluator-blinded, controlled study of the effectiveness and safety of small gel particle hyaluronic acid for lip augmentation. *Dermatol Surg.* 2012;38:1180-1192.
- Cohen JL, Dayan SH, Brandt FS, et al. Systematic review of clinical trials of small- and large-gel-particle hyaluronic acid injectable fillers for aesthetic soft tissue augmentation. *Dermatol Surg.* 2013;39:205-231.
- Reuther T, Bayrhammer J, Kerscher M. Effects of a three session skin rejuvenation treatment using stabilized hyaluronic acid-based gel of non-animal origin on skin elasticity: a pilot study. *Arch Dermatol Res.* 2010;302:37-45.
- Williams S, Tamburic S, Stensvik H, et al. Changes in skin physiology and clinical appearance after microdroplet placement of hyaluronic acid in aging hands. *J Cosmet Dermatol.* 2009;8:216-225.
- Kerscher M, Bayrhammer J, Reuther T. Rejuvenating influence of a stabilized hyaluronic acid-based gel of nonanimal origin on facial skin aging. *Dermatol Surg.* 2008;34:720-726.
- Gubanova EI, Starovatova PA, Rodina MY. 12-month effects of stabilized hyaluronic acid gel compared with saline for rejuvenation of aging hands. *J Drugs Dermatol.* 2015;14:288-298.
- Gubanova EI, Dyachenko YY, Rodina MY, et al. New hydrobalance technology based on stabilized hyaluronic acid for long-term skin hydration. *Esteticheskaia Meditsina (Aesthetic Medicine).* 2010;1:94-1098.
- Distante F, Pagani V, Bonfigli A. Stabilized hyaluronic acid of non-animal origin for rejuvenating the skin of the upper arm. *Dermatol Surg.* 2009;35:389-393.
- Roh NK, Kim MJ, Lee YW, et al. A split-face study of the effects of a stabilized hyaluronic acid-based gel of nonanimal origin for facial skin rejuvenation using a stamp-type multineedle injector: a randomized clinical trial. *Plast Reconstr Surg.* 2016;137:809-816.

- Beer K, Glogau RG, Dover JS, et al. A randomized, evaluator-blinded, controlled study of effectiveness and safety of small particle hyaluronic acid plus lidocaine for lip augmentation and perioral rhytides. *Dermatol Surg.* 2015;41:s127-s136.
- Kim J. Effects of injection depth and volume of stabilized hyaluronic acid in human dermis on skin texture, hydration, and thickness. *Arch Aesthetic Plast Surg.* 2014;20:97-103.
- Ribé A, Ribé N. Neck skin rejuvenation: histological and clinical changes after combined therapy with a fractional non ablativ laser and stabilized hyaluronic acid-based gel of non-animal origin. *J Cosmet Laser Ther.* 2011;3:154-161.
- Landau M. Hyaluronic acid "skinboosters" and use of blunt injection micro-cannulas. *J Drugs Dermatol.* 2012;11:41-43.
- Halachmi S, Ben Amitai D, Lapidot M. Treatment of acne scars with hyaluronic acid: an improved approach. *J Drugs Dermatol.* 2013;12:e121-e123.
- Di Gregorio C, D'Arpa S. Therapeutic use of hyaluronic acid fillers in the treatment of corticosteroid-induced skin and subcutaneous atrophy. *Dermatol Surg.* 2016;42:1307-1310.
- Driskell RR, Jahoda CA, Chuong CM, et al. Defining dermal adipose tissue. *Exp Dermatol.* 2014;23:629-663.
- Lawlor KT, Kaur P. Dermal contributions to human interfollicular epidermal architecture and self renewal. *Int J Mol Sci.* 2015;16:28098-28107.
- Landau M, Fagien S. Science of hyaluronic acid beyond filling: fibroblasts and their response to the extracellular matrix. *Plast Reconstr Surg.* 2015;136:188s-195s.
- Fisher GJ, Varani J, Voorhees JJ. Looking older: fibroblast collapse and therapeutic implications. *Arch Dermatol.* 2008;144:666-672.
- Kruglikov IL, Scherer PE. Skin aging: are adipocytes the next target? *Aging.* 2016;8:1457-1469.
- Kruglikov IL, Wollina U. Soft tissue fillers as non-specific modulators of adipogenesis: change of the paradigm? *Exp Dermatol.* 2015;24:912-915.

## AUTHOR CORRESPONDENCE

### Magda Belmontesi MD

E-mail:..... studiobelmontesi@pelleedintorni.it